

Bilateral Anatomical Variations in the Formation, Communication and the Termination of the Retromandibular Vein

VEENA VIDYA SHANKAR, DIVYA CHANDRASHEKAR, SHESHGIRI CHOWDAPURKAR

ABSTRACT

A sound knowledge of variations of superficial and deep veins of Head & Neck region is important during operative, diagnostic and endovascular procedures of head and neck to surgeons, interventional radiologists and clinicians. The objective of this

case report was to bring awareness to the clinicians about the variations in the veins of head & neck in general & the RMV specifically. The clinical, surgical and embryological significance of these variations have been emphasised.

Key Words: Retromandibular vein, Variations, External jugular vein, Internal jugular vein, Facial vein

INTRODUCTION

The veins of the head and neck have a complex developmental pattern which predisposes them to variations in their formation and drainage. The standard anatomical description of the veins of the face is the superficial temporal vein uniting with the maxillary vein to form the Retromandibular Vein (RMV) within the substance of the parotid gland. The RMV divides into the anterior and the posterior divisions. The anterior division joins with the facial vein, inferior to the angle of the mandible, to form the common facial vein that drains into the internal jugular vein. The posterior division joins with the posterior auricular vein to form the external jugular vein which drains into the subclavian vein [1,2].

The knowledge on the varied drainage patterns of the veins of the head and neck is important and relevant, as they are often used for cannulation in intravenous infusions, central venous pressure monitoring and in microvascular anastomosis. The surgeons can also avoid any unnecessary bleeding during the intraoperative trial and error procedures [3]. RMV is an important anatomical element in radiology which can be used to localize a tumour in the parotid gland in relation to the facial nerve and in surgery, as a landmark to dissect the facial nerve and its branches.

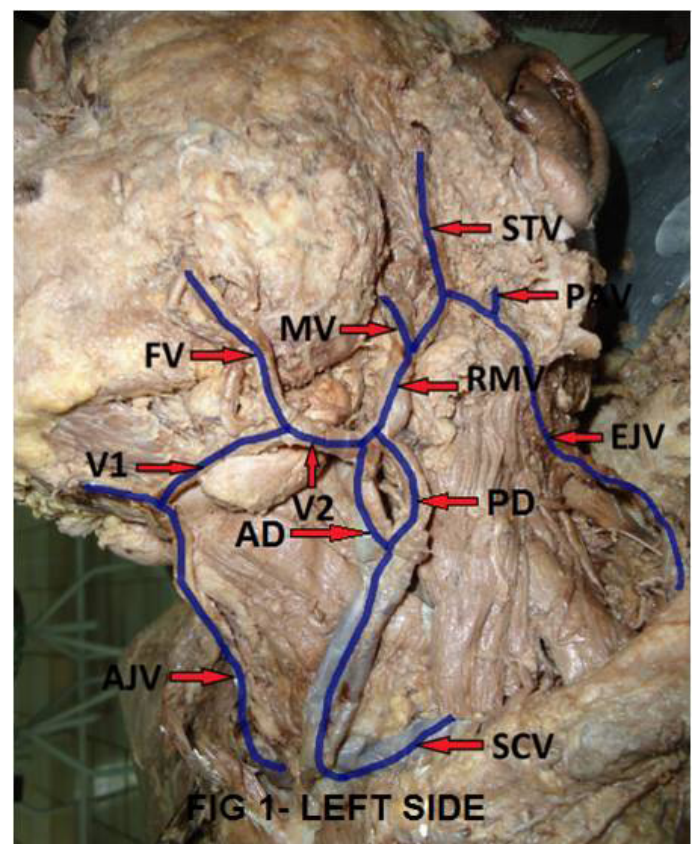
MATERIAL AND METHODS

During the routine cadaver dissection in the Department of Anatomy at M.S.Ramaiah Medical College, variations of the major veins of the head and neck region were observed in a 60yr old male cadaver. The part was neatly dissected and photographs were taken.

OBSERVATION

On the left side [Table/Fig-1], the superficial temporal vein bifurcated into the anterior and the posterior divisions. The anterior division joined with the maxillary vein to form the RMV. The posterior division joined with the posterior auricular vein to form the external jugular vein which drained into the subclavian vein. The RMV divided into the anterior and the posterior divisions at the angle of the mandible. A connecting venous channel-V1 which measured 3.8cms, ran superficial to the submandibular gland and was connected to the

facial vein and the single anterior jugular vein to form a common venous channel – V2 which measured 1.6cms, which drained into the beginning of the anterior division of the RMV. About 2.5cm distal to this drainage, the anterior division of the RMV opened into the internal jugular vein [Table/Fig-1A]. Further, the anterior division continued and joined the posterior division of the RMV to form a single vein at the junction of the lower and the middle third of the sternocleidomastoid, and drained into the left subclavian vein.



[Table/Fig-1] Left side: Retromandibular vein – formation, communication & termination.

STV- Superficial temporal vein, MV - Maxillary vein, PAV - Posterior auricular vein, RMV - Retromandibular vein, FV- Facial vein, EJV - External jugular vein, V1 & V2 - Communicating channels, AD - anterior division, PD - posterior division, AJV-Anterior jugular vein, SCV - Subclavian vein.

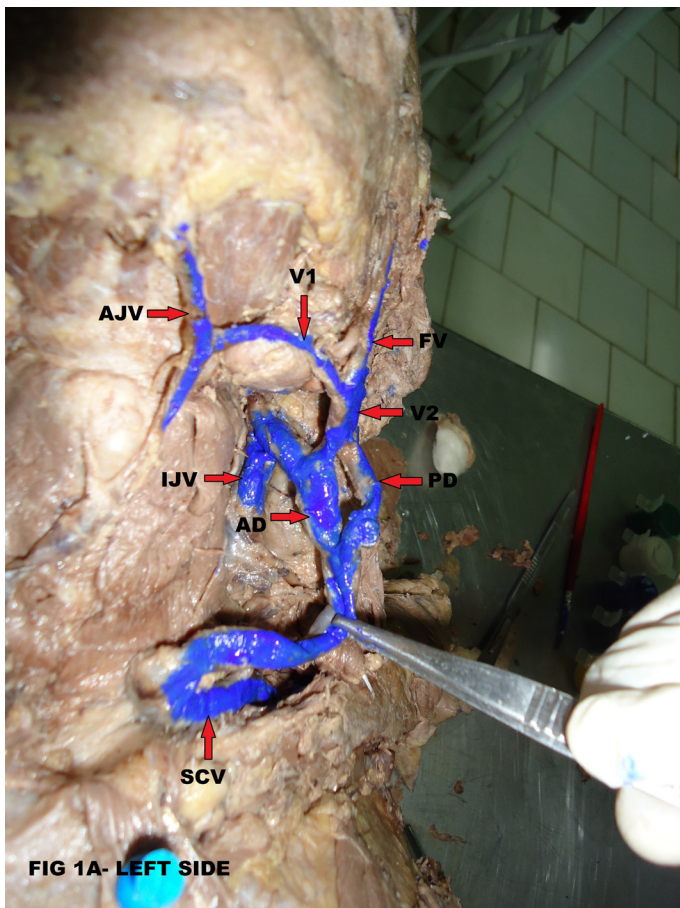


FIG 1A- LEFT SIDE

[Table/Fig-1A] Left side: Anterior division of RMV draining into internal jugular vein

FV - Facial vein, AJV - Anterior jugular vein, V1 & V2 - Communicating channels, AD - anterior division, PD - posterior division, IJV - Internal jugular vein, SCV - Subclavian vein.

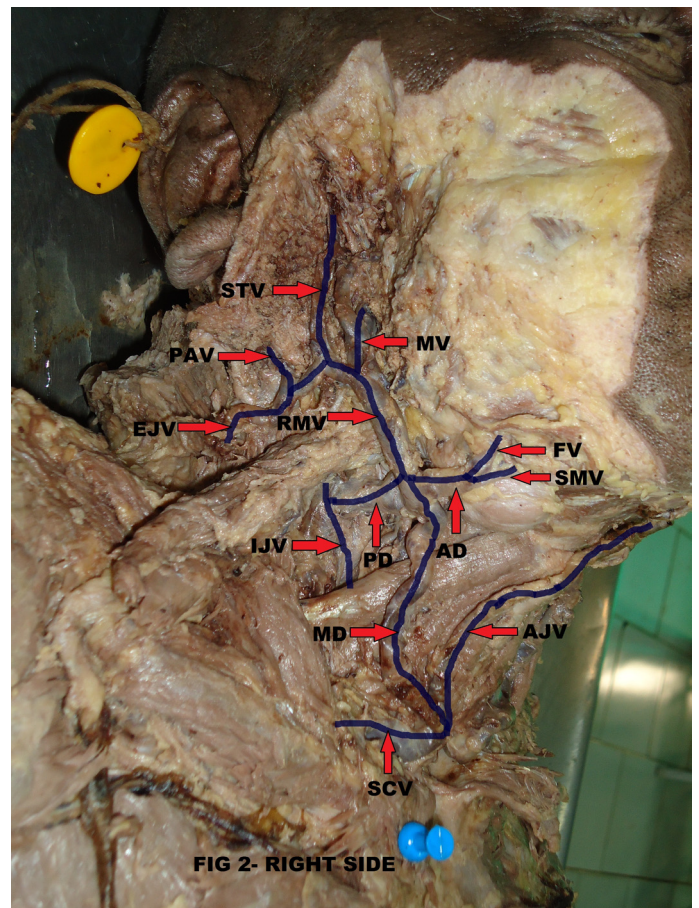


FIG 2- RIGHT SIDE

[Table/Fig-2] Right side: Retromandibular vein – formation, communication & termination.

STV - Superficial temporal vein, MV - Maxillary vein, PAV - Posterior auricular vein, EJV - External jugular vein, RMV - Retromandibular vein, AD - anterior division, MD - middle division, PD - posterior division, FV - Facial vein, SMV - Submandibular vein, AJV - Anterior jugular vein, SCV - Subclavian vein, IJV - Internal jugular vein.

On the right side [Table/Fig-2], the superficial temporal vein bifurcated into the anterior and the posterior divisions. The anterior division joined with the maxillary vein to form the RMV. The posterior division joined with the posterior auricular vein to form the external jugular vein which drained into the subclavian vein. The RMV trifurcated at the angle of the mandible. The anterior division received the facial vein and the submandibular vein. The middle division continued downwards and forwards and it joined with the anterior jugular vein, which is a single vein and it drained into the subclavian vein. The posterior division drained into the internal jugular vein.

DISCUSSION

The venous drainage of the head and neck region gets established after the formation of the skull. The first vessel that can be identified is the ventral pharyngeal vein which drains the mandibular and the hyoid arches to the cranial part of the precardinal vein – the future internal jugular vein. The ventral pharyngeal vein receives tributaries from the face and the tongue and it becomes the linguofacial vein. It anastomoses with the primitive maxillary vein to form the facial vein, which receives a strong tributary from the temporal region – the RMV and it drains into the internal jugular vein through the linguofacial vein. The external jugular vein arises from the neck region from a tributary of the cephalic vein [1]. The variations in the size and the pattern of the veins of the neck are quite common [2]. There have been cases which have been reported, where the facial vein terminated into the external jugular vein [4]; the RMV united with the facial vein at a higher level in the parotid gland [5]; the facial vein drained into the superficial temporal vein with an undivided

RMV; the right facial vein drained into the superficial temporal vein, about 5mm above an undivided RMV [6]; and the common trunk of the RMV joined with the anterior facial vein to form the common facial veins, with the absence of the external jugular vein bilaterally. The anomalous venous patterns are due to the regression and / or the retention of the venous anastomotic channels [7].

The superficial temporal vein and the RMV have been used as guides to expose the facial nerve branches in the parotid gland in superficial parotidectomy and also in cases of open reductions of the mandibular condyle fractures [8]. These veins are usually used as grafts during carotid endarterectomy and surgical microvascular anastomosis, especially in oral reconstruction procedures [9]. Any malformations and variations of the veins of head and neck should be kept in mind preoperatively, as this helps the surgeons in planning the operative procedures [10].

CONCLUSION

To conclude, the bilateral spectrum of the anatomic variations in the formation, communication and the termination of RMV makes this a rare, special case.

REFERENCES

- [1] Standring S. Gray's Anatomy - The Anatomical Basis of the Clinical Practice. 39th edition. Edinburgh: Elsevier Churchill Livingstone; 2006. 793-794, 225-26.
- [2] Hollinshead W H. Anatomy for surgeons -The Head and Neck. 3rd edition. New York: Harper and Row publishers; 1968; 530.
- [3] Mehra S, Kaul JM, Das S. An unusual venous drainage pattern of the

- face – a case report. *J. Anat Soc. India*. 2003; 52: 84-85.
- [4] Peuker ET, Fischer G, Filler TJ. The facial vein terminating in the superficial temporal vein: a case report. *J. Anat.* 2001;198: 509-10.
- [5] Kopuz C, Ilgi S, Yavuz S, Onderoglu S. Morphology of the retromandibular vein in relation to the facial nerve in the parotid gland. *Acta Anatomica* (Basel). 1995a; 152(1): 66-68.
- [6] Yadav S, Ghosh SK, Anand SC. Variations of the superficial veins of the head and neck. *J. Anat Soc India*. 2000; 49: 61-62.
- [7] Bertha A, Rabi S. The anatomical variations in the termination of the common facial vein. *Journal of Clinical and Diagnostic Research*. 2011 Feb; 5(1):24-27.
- [8] Kawakami S, Tsukada S, Taniguchi W. The superficial temporal and the retromandibular veins as guides for exposing the facial nerve branches. *Annals of Plastic Surgery*. 1994; 32(2): 295-99.
- [9] Sabharwal P, Mukerjee D. The autogenous common facial vein or an external jugular vein patch for carotid endarterectomy. *Cardiovascular Surgery*. 1998; 6: 594-97.
- [10] Choudhary S, Sharma AK, Singh H. The undivided retromandibular vein continuing as the external jugular vein with the facial vein draining into it: An anatomical variation. *J K Science*. Dec 2010; 12 (4): 203-04.

AUTHOR(S):

1. Dr. Veena Vidya Shankar
2. Dr. Divya Chandrashekar
3. Dr. Sheshgiri Chowdapurkar

PARTICULARS OF CONTRIBUTORS:

1. Assistant Professor, Department of Anatomy, M.S.Ramaiah Medical College, Bangalore. Karnataka, 560054, India.
2. Post Graduate Student, Department of Anatomy, M.S.Ramaiah Medical College, Bangalore. Karnataka, 560054, India.
3. Senior Professor and Head of the Department, Department of Anatomy, M.S.Ramaiah Medical College, Bangalore. Karnataka, 560054, India.

NAME, ADDRESS, E-MAIL ID OF THE CORRESPONDING AUTHOR:

Dr. Veena Vidya Shankar,
Assistant Professor, Department of Anatomy,
MS Ramaiah Medical College,
MSRIT Post, Bangalore, Karnataka-560054, India.
Phone: 9980308735, 080-23355472
E-mail: veena24shankar@gmail.com.

FINANCIAL OR OTHER COMPETING INTERESTS:

None.

Date of Submission: **May 16, 2012**

Date of Peer Review: **Jun 01, 2012**

Date of Acceptance: **Aug 25, 2012**

Date of Publishing: **Sep 30, 2012**